ER BASICS · ONE-PAGER

Trauma: Primary and Secondary Survey

xABCDE priorities, hemorrhage control, shock classes, damage control resuscitation and chest injuries for trauma exams

47 sources + more detail
erbasics.com/sheets/trauma-primary-survey.html
checked Nov 2026

CONTROL Hemorrhage control you will inherit

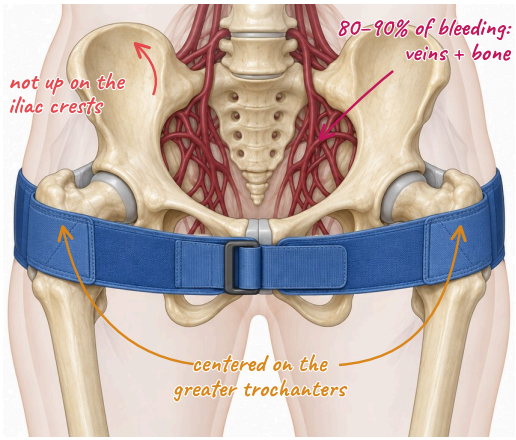

1 Primary survey: xABCDE

ATLS 11 (xABCDE, 2025) and PHTLS (XABCDE) stop exsanguinating bleeding before the airway; TNCC 9th edition switches to C-ABC for uncontrolled bleeding.

STEP	LOOK FOR	DO
x	Spurting or pooling blood	Pressure, tourniquet, hemostatic packing
A	Obstruction, face or neck injury, burns	Open and protect; limit spine motion if blunt
B	Distress, unequal breath sounds, low SpO2	Oxygen; decompress tension; seal open wounds
C	Shock; chest, abdomen, pelvis, femur bleeding	IV or IO, blood, pelvic binder, eFAST
D	GCS, pupils, lateralizing signs, glucose	Prevent hypoxia and hypotension
E	Hidden wounds, temperature	Expose fully, then warm

EXAM TIP Exams: bleeding control comes first, and blood comes before intubating a hypotensive patient; post-intubation hypotension is linked to worse survival.

2 Hemorrhage control

- Tourniquet on skin 2–3 inches above the wound; "high and tight" if the source is unclear
- Tighten until bleeding stops and the distal pulse is gone; add a second beside it if needed
- Mark the time; don't loosen it to "check" the wound
- Junctional wounds: junctional tourniquet if one fits, or pack hemostatic gauze and press 3+ minutes
- Suspected pelvic fracture: binder or sheet centered on the greater trochanters; too high is the common error

SAFETY After 6 hours, a tourniquet comes off only with close monitoring and labs available.

3 Hemorrhagic shock classes

Base deficit worsens by class (about −2, −6, −10 mEq/L). Class III needs blood; class IV, massive transfusion.

CLASS	LOSS (70-KG ADULT)	WHAT YOU SEE
I	<15% (<750 mL)	Near-normal vital signs
II	15–30% (750–1,500 mL)	HR normal or up, narrow pulse pressure, BP normal
III	31–40% (1,500–2,000 mL)	HR up, BP may fall, confused, low urine output
IV	>40% (>2,000 mL)	HR high, hypotension, lethargy, little urine

EXAM TIP Hypotension first appears in class III. Age, beta-blockers and pacemakers blunt tachycardia, so add shock index (HR ÷ SBP; worry near 1), lactate and base deficit.

4 Damage control resuscitation

- Permissive hypotension until bleeding stops: SBP 80–90 (MAP 50–60) mm Hg
- Not for TBI (SBP 110+; MAP 80+ if GCS 8 or less) or spinal injury; caution if older or hypertensive
- Little crystalloid; early whole blood, or plasma, platelets and RBCs near 1:1:1
- MTP trigger, ABC score 2+: penetrating torso injury, SBP <90, HR >120, positive FAST
- TXA within 3 hours for hemorrhagic shock (often SBP <90 or HR >110): 1 g IV over 10 min, then 1 g over 8 h; EMS may give 2 g once
- Calcium: citrate in blood binds it; TCCC gives 1 g after the first unit; keep iCa 1.1–1.3 mmol/L
- Triad of death: hypothermia (<35 °C), acidosis, coagulopathy; low iCa makes the "lethal diamond"; cold crystalloid worsens all

SAFETY Never start TXA more than 3 hours after injury: in CRASH-2, late doses raised deaths from bleeding. Doses are typical adult ranges for exam study; follow your institution's or agency's protocols.

5 Chest injuries that kill fast

Adult needle sites: 4th–5th space just anterior to the midaxillary line, or 2nd midclavicular (not medial to the nipple); about 8 cm. Decompression follows protocol; nurses recognize, prepare and assist.

INJURY	KEY SIGNS	INTERVENTION
Tension pneumothorax	Absent breath sounds, hyperresonant; late: low BP, JVD, tracheal shift	Needle decompression, then finger or tube thoracostomy
Massive hemothorax	Shock, decreased breath sounds, dull, neck veins usually flat	Blood, chest tube; surgery if >1,500 mL initially or >200 mL/h for 2–4 h
Open pneumothorax	Sucking or bubbling wound	Vented seal (else non-vented or 3-sided); chest tube; watch for tension
Flail chest	2+ (some say 3+) adjacent ribs broken in 2+ places; paradoxical motion	Oxygen, analgesia, ventilation if failing; watch the contusion
Traumatic asphyxia	Chest crush: purple face and neck, petechiae, bloodshot eyes	A marker of chest crush: oxygen; look for contusion, flail, pneumothorax
Cardiac tamponade	Beck triad, pulsus paradoxus >10 mm Hg, PEA; positive FAST	Volume, pericardiocentesis to buy time, surgery

EXAM TIP Tension pneumothorax is a clinical diagnosis: decompress before the x-ray. Neck veins may be flat if the patient is also bleeding. Burp a chest seal if distress worsens.

6 Secondary survey, head and spine

- Begins after the primary survey and initial resuscitation; any decline sends you back to xABC
- AMPLE: allergies, medications (anticoagulants, beta-blockers), past illness or pregnancy, last meal, events
- Head-to-toe exam, log roll to inspect the back, then CT
- TNCC: F–G close the primary survey (full vitals/family presence, adjuncts/comfort); H–I are the secondary (history/head-to-toe, inspect the back); J: keep reevaluating
- TBI: SpO2 above 90%, EtCO2 35–45; hyperventilate to EtCO2 30–35 only for herniation signs
- Spinal motion restriction after blunt trauma with altered mentation, midline tenderness, focal deficit, deformity, intoxication or distracting injury; not for isolated penetrating trauma

MORE Brain and spinal cord injury in the first hours

The first hours are about preventing secondary brain injury. A single SBP below 90 or PaO_2 below 60 roughly doubled mortality in the Traumatic Coma Data Bank, and when Arizona EMS adopted the prehospital TBI guidelines (EPIC, Spaite 2019), adjusted survival doubled in severe TBI and tripled in intubated patients.

For education and exam preparation only. Not medical advice; follow current guidelines and your institution's protocols. ER Basics is an independent study aid not affiliated with any certifying body.