ER BASICS · ONE-PAGER

Pulmonary Embolism

ESC 2019 and AHA/ACC 2026 risk classes, diagnosis, anticoagulation, lysis, catheter therapy and RV support

28 sources + more detail
erbasics.com/sheets/pulmonary-embolism.html
checked Nov 2026

PATHO Why the RV fails

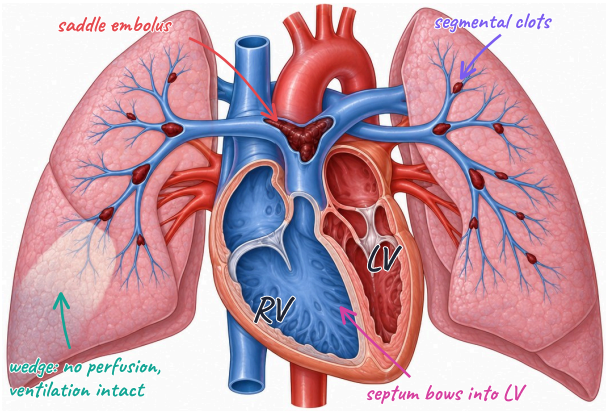

1 Risk classes: ESC 2019 and AHA/ACC 2026

Mapping approximate (CMAJ 2026); R modifier: hypoxemia or rising O_2 need.

ESC 2019	AHA/ACC 2026	DEFINING FEATURES
Low	A, B	A: incidental. B: PESI I–II or sPESI 0
Intermediate-low	C1, C2	PESI III–V or sPESI ≥1; RV strain, biomarker: none or one
Intermediate-high	C3	Score up plus RV dysfunction and troponin (AHA/ACC: or BNP)
Intermediate-high	D1, D2	D1 transient hypotension; D2 normotensive shock (lactate >2)
High	E1, E2	Shock or SBP <90 (or fall ≥40) >15 min; E2: refractory, arrest

- RV dysfunction: RV/LV ≥1.0 on CT or echo, TAPSE <16 mm, McConnell or 60/60 sign
- Biomarkers: troponin, NT-proBNP ≥600 pg/mL; lactate ≥2 mmol/L predicts complications (ESC 2019)
- sPESI, 1 point each: age >80, cancer, chronic heart or lung disease, HR ≥110, SBP <100, SaO_2 <90%; 0 = 1.0% 30-day mortality, ≥1 = 10.9%

2 Diagnosis: unstable vs stable

PATIENT	APPROACH
Shock or hypotension	Heparin now; bedside echo or CTPA, whichever is faster
Unstable, CT not feasible	RV overload on echo, no other cause: treat as high risk
Stable, gestalt <15%	All 8 PERC criteria negative: no testing
Stable, Wells ≤4	D-dimer: age × 10 µg/L over age 50, or YEARS
Stable, Wells >4	CTPA; D-dimer cannot exclude PE
Contrast allergy or severe CKD	V/Q scan; proximal DVT on ultrasound confirms VTE

YEARS: no items (DVT signs, hemoptysis, PE most likely) and D-dimer <1,000 ng/mL, or any item and <500, excludes PE. A normal echo cannot exclude PE when stable.

3 Anticoagulation

- Start during workup if probability is intermediate or high (ESC 2019)
- LMWH over UFH in C1 to E1 (AHA/ACC 2026, Class 1; 2a if a procedure is likely): enoxaparin 1 mg/kg every 12 h
- UFH 80 units/kg, then 18 units/kg/h: E2, ECMO, CrCl ≤30; ESC 2019 also when reperfusion is planned
- Alteplase: hold heparin, restart at aPTT ≤2× normal (US label); ESC 2019 lets UFH run
- DOAC once stable, after 2–3 days if intermediate-high (ESC 2019); not in pregnancy or antiphospholipid syndrome

4 Reperfusion and the PE response team

THERAPY	DOSE OR METHOD	AHA/ACC 2026 USE
Systemic alteplase	100 mg IV over 2 h (label)	First choice in E2; 2a in E1; 2b in D, C3
Arrest or extremis	50 mg bolus common, or 0.6 mg/kg (max 50) over 15 min	CPR 60–90 min after a lytic (ESC 2019)
Catheter-directed lysis	Low-dose alteplase via PA catheters	2a in E1; 2b in C2 to D
Mechanical thrombectomy	Large-bore aspiration, no lytic	2a in E1; 2b in C2 to D
Surgical embolectomy	Lysis failed or contraindicated	2a in E1; 2b in D
VA-ECMO	Bridge to reperfusion or recovery	2a in E2

Systemic lysis is harmful in A to C2. PEITHO (tenecteplase, intermediate-high): death or collapse 2.6% vs 5.6%, hemorrhagic stroke 2.0% vs 0.2%. HI-PEITHO (2026): catheter lysis 4.0% vs 10.3%, no intracranial bleeds. PERT review: Class 1 for C to E.

Absolute contraindications (ESC 2019): hemorrhagic or unexplained stroke, ischemic stroke in 6 months, CNS tumor, major trauma, surgery or head injury in 3 weeks, bleeding diathesis, active bleeding.

5 Supporting the failing RV

- Fluids: none if CVP is high; ≤500 mL over 15–30 min only if CVP is low (ESC 2019)
- Norepinephrine first: keeps aortic above RV pressure; vasopressin second
- Dobutamine for low output once MAP holds; inhaled NO or epoprostenol as a bridge
- Oxygen for SaO_2 <90%; high-flow nasal cannula or NIV rather than intubation

⚠ SAFETY Intubation can trigger arrest: induction drops SVR, positive pressure cuts venous return, apnea raises CO_2 and PVR. If unavoidable: norepinephrine running, expert operator, preoxygenate, reduced-dose etomidate or ketamine, VT 6 mL/kg, plateau <30, low PEEP, ECMO team aware.

6 Nursing: monitoring and bleeding watch

- Trend HR, BP, shock index (HR ÷ SBP >1), lactate, urine output, O_2 need; escalate early
- Before lysis: 2 IVs, CBC, fibrinogen, aPTT, type and screen; lines first, then no IM or noncompressible sticks
- During and after: frequent neuro checks and vitals; check sites, urine, stool, flank pain
- Headache, vomiting, new deficit or falling GCS: stop lytic and heparin, stat head CT
- Major bleeding: cryoprecipitate to fibrinogen ≥150 mg/dL, tranexamic acid, protamine for UFH

💡 EXAM TIP Exams test: hypotension, not clot size, decides lysis; normotensive RV strain plus troponin: anticoagulate, monitor, rescue if worse; no big fluid boluses.

MORE Pathophysiology: why the RV fails

Most emboli start in proximal leg or pelvic veins; ultrasound finds a DVT in 30–50% of patients with PE (ESC 2019). PA pressure rises once more than 30–50% of the pulmonary bed is occluded, and thromboxane A_2, serotonin and hypoxic vasoconstriction add to the block. A previously normal RV cannot generate a mean PA pressure above about 40 mm Hg (ESC 2019), so acute PE presents as RV failure rather than as very high PA pressures.

The dilated RV contracts longer and bows the septum into the LV in early diastole; right bundle branch block adds desynchrony. LV filling, output and BP fall, and the RV becomes ischemic (troponin release) and fails further. Inflammation can destabilize a patient again 24–48 h later (ESC 2019).

Hypoxemia comes from V/Q mismatch and low mixed venous saturation. About a third of patients shunt right to left through a patent foramen ovale, risking paradoxical embolism. Dead space widens the $PaCO_2$–$EtCO_2$ gap, $PaCO_2$ is usually low, and up to 40% have a normal SaO_2 (ESC 2019).

For education and exam preparation only. Not medical advice; follow current guidelines and your institution's protocols. ER Basics is an independent study aid not affiliated with any certifying body.