ER BASICS · ONE-PAGER

Pressure Injury Staging and Wound Care

Staging in plain words, prevention, wound assessment, dressings by wound bed, healing, drains and wound vacuums, dehiscence and infection

20 sources + more detail
erbasics.com/sheets/pressure-injury-wound-care.html
checked Oct 2026

ANATOMY Staging by the deepest tissue

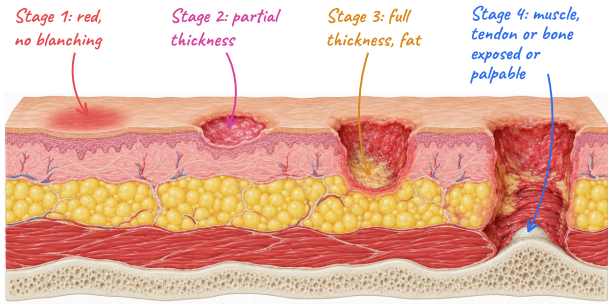

1 Staging by the deepest tissue

CATEGORY	WHAT YOU FIND	WATCH
Stage 1	Intact skin, red area that does not blanch when pressed	Dark skin: warmth, firmness, swelling or a color change instead of visible redness
Stage 2	Partial thickness: shallow, pink-red moist bed, or an intact or broken clear blister	No fat, slough or eschar; not moisture damage or a skin tear
Stage 3	Full thickness: fat visible; slough, eschar, undermining or tunneling possible	No exposed bone, tendon, ligament, muscle or cartilage
Stage 4	Full thickness with fascia, muscle, tendon, ligament, cartilage or bone exposed or directly palpable (NPIAP 2016)	Slough or eschar may be present; rolled edges, undermining, tunneling; osteomyelitis is a complication, not part of the definition
Unstageable	Full thickness, but slough or eschar hides how deep it goes	Stable dry eschar on a heel or ischemic limb is left on
Deep tissue	Persistent maroon, purple or deep red area, or a blood-filled blister; may feel boggy	Can open fast to a deep wound, or resolve
Device-related	Shaped like the device (mask, tube, collar, probe)	Names the cause; stage it on the scale above
Mucosal	On lips, tongue, nose lining, urethra from a tube	Not staged

EXAM TIP Never reverse-stage: a healing stage 4 is documented as a healing stage 4. Blanching redness is reactive, not stage 1; recheck after offloading.

2 Not a pressure injury

WOUND	TYPICAL PICTURE	CORE CARE
Incontinence dermatitis	Diffuse shiny redness or erosion in skin exposed to urine or stool, blurred edges	Cleanse after each episode with a pH-balanced cleanser, pat dry, barrier cream, breathable pad; no soap scrubs or powder
Skin tear	Fragile older or steroid-thinned skin torn by shear or a bump	Nonadherent dressing; protect fragile skin from shear
Venous ulcer	Medial lower leg, irregular, moist, brown staining, edema	Compression, legs above the heart, daily walking
Arterial ulcer	Toes, feet, heels; punched out, painful, may turn black	No compression unless cleared; report to the provider
Neuropathic (diabetic)	Sole or toes under pressure points, often painless	Offload, daily foot checks, well-fitting shoes

3 Prevention

- Assess risk on admission and with any change, with a validated risk scale plus judgment; in ICU, shock and vasopressors add risk
- Inspect skin daily, in good light, over bony areas and under every device; feel for warmth or bogginess
- Turn at least every 2 h (individualized), 30° side tilt; lift with sheets or devices, never drag
- Head of bed at 30° or lower when allowed, to limit sliding and shear
- Float heels: pillow under the calves, not the knees, or a heel boot
- Chair: shift weight about every 15 min; foam or gel cushion; no donut rings
- Pressure-redistributing mattress for clients at risk; pad and move devices
- Moisture: clean promptly after incontinence, barrier product, no talc or harsh soap
- Nutrition: dietitian referral; with an injury, about 30–35 kcal/kg and 1.25–1.5 g/kg protein a day

4 Assess and document

- Location and type; stage only pressure injuries
- Size in cm at every change: length head to toe, width side to side, depth with a sterile applicator
- Undermining and tunneling by clock face, 12:00 toward the head; never force the probe
- Bed: % red granulation, yellow slough, black eschar
- Drainage: serous, sanguineous, serosanguineous, purulent; amount by % of dressing soaked (under 25%, 25–75%, over 75%)
- Edges and surrounding skin: maceration, induration, redness; odor; pain (premedicate before painful changes)

5 Dressing by wound bed

WOUND BED	CHOOSE
Stage 1 or friction-prone skin	Offload; transparent film or silicone foam to protect
Shallow, little drainage	Film, hydrocolloid or hydrogel
Slough, little drainage	Hydrogel or hydrocolloid to soften it (autolytic); not if infected
Heavy drainage or deep cavity	Alginate or gelling fiber (fill loosely), foam on top; never on a dry bed
Dry stable heel eschar	Leave it; offload and check daily

Clean with normal saline, not peroxide or povidone-iodine. Keep the bed moist and the skin around it dry. Wet-to-dry gauze removes healthy tissue with the dead and hurts, so it is not a first choice.

6 Healing and infection

INTENTION	WOUND
Primary	Edges closed (sutures, staples, glue): incisions
Secondary	Left open, fills with granulation: pressure injuries; more infection risk
Tertiary	Left open, closed later (delayed closure), often after infection

Local infection: spreading redness, warmth, induration, new pain, purulent or foul drainage. Systemic: fever over 38 °C (100.4 °F). Report and anticipate a culture: tissue rather than a swab of drainage; chronic wounds are colonized, so no routine swabs. A septic incision may be opened by the surgeon.

7 Drains and wound vacuums

- JP or Hemovac: empty, measure, squeeze the bulb flat and cap to restore suction; keep it below the wound; record as output
- Report a change in amount, frank blood or pus; falling output may mean it is ready to come out
- Wound vacuum working: foam collapsed and firm, pump quiet, serosanguineous drainage
- Alarm or loose dressing: find and patch the leak; off or not working for more than 2 h: remove the foam and replace the dressing per the device instructions
- Count foam pieces in and out; never cut foam over the wound

SAFETY Bright red blood filling the vacuum tubing or canister: stop the therapy, leave stuck foam in place, check vital signs and call the provider now.

8 Dehiscence and evisceration

SAFETY Wound opens or organs show: stay with the client and send for the surgeon. Low Fowler with knees bent, cover with sterile saline-moistened gauze, keep NPO, check vital signs for shock. Never push organs back.

Warning signs: a gush of serosanguineous fluid, "something gave way" with a cough, no healing ridge by days 5–9. Prevent: splint the incision to cough, avoid heavy lifting.

For education and exam preparation only. Not medical advice; follow current guidelines and your institution's protocols. ER Basics is an independent study aid not affiliated with any certifying body.