ER BASICS · ONE-PAGER

Pericarditis, Effusion and Tamponade

Diagnosis, ECG vs STEMI, colchicine and recurrence, tamponade signs and drainage, postoperative and post-MI syndromes

26 sources + more detail
erbasics.com/sheets/pericardial-disease.html
checked Oct 2026

PHYSIOLOGY Why a full sac stops the heart

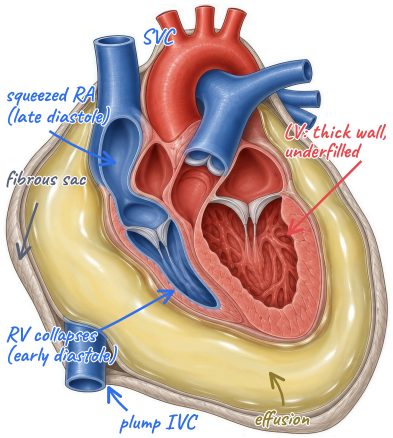

1 Acute pericarditis: diagnosis and triage

2025 ESC and ACC criteria add raised CRP and CMR pericardial inflammation.

ESC 2015: any 2 of 4	How often
Sharp pleuritic pain, eased by sitting forward	85–90%
Pericardial friction rub	Up to 33%
New widespread ST elevation or PR depression	Up to 60%
New or larger pericardial effusion	Up to 60%

Work-up: ECG, echo, CRP, troponin, chest x-ray. Admit (ESC 2015) for any of: fever >38 °C, subacute onset, effusion >20 mm, tamponade, no NSAID response in 1 week, myopericarditis, immunosuppression, trauma, oral anticoagulant.

2 ECG: pericarditis or STEMI?

Feature	Pericarditis	STEMI
ST elevation	Diffuse, concave, many territories	One territory, convex or straight
Reciprocal depression	Only aVR and V1	Opposite leads
PR segment	Depressed; elevated in aVR	Usually normal
ST elevation III > II	Unusual	Strongly suggests STEMI
T inversion	After ST normalizes	With ST still raised

Stages: ST up with PR down (first 2 weeks), flat T, inverted T, normal; under half show all four (LITFL).

EXAM TIP Exams: diffuse concave ST elevation, PR depression, no reciprocal change except aVR and V1 = pericarditis. Troponin rise, normal LV function = myopericarditis; exclude ACS.

3 Drugs, recurrence and exercise

Full dose 1–2 weeks, then taper by pain and CRP (ESC 2015, ACC 2025).

Drug	Typical adult dose	Notes
Aspirin	750–1,000 mg every 8 h	After MI or CABG, or on antiplatelets
Ibuprofen	600–800 mg every 8 h	Add a PPI to either
Colchicine	0.5–0.6 mg twice daily; daily if <70 kg	3 months (6 if recurrent); halves recurrence (ICAP)
Prednisone	0.2–0.5 mg/kg/day, slow taper	Second line; exclude infection
Rilonacept, anakinra	Rilonacept 320 mg, then 160 mg weekly; anakinra 100 mg daily	SC IL-1 blockers: recurrent, CRP high

Steroids ease pain fast but favor recurrence (ESC 2015); 1 mg/kg/day did worse than 0.2–0.5 (HR 3.61, Imazio 2008).

Colchicine: diarrhea; avoid with strong CYP3A4 or P-gp inhibitors (clarithromycin, azoles, ritonavir, cyclosporine) or severe renal impairment. Avoid anticoagulants when possible (hemopericardium). No strenuous exercise for ≥1 month and until remission (ACC, ESC 2025).

4 Effusion or tamponade?

Speed beats size: the pericardium stretches slowly, then not at all. Large effusion: >20 mm (ESC 2015).

Finding	In tamponade	Note
Beck's triad	Low BP, JVD, muffled heart sounds	Late, often incomplete
Pulsus paradoxus	Inspiratory SBP fall >10 mm Hg	82% sensitive; ≤10 makes it unlikely (Roy 2007)
ECG	Tachycardia, low voltage, electrical alternans	Swinging heart
PA catheter	CVP, PAD and PAOP equal, 15–30 mm Hg	Blunted y descent
Echo	RA and RV diastolic collapse, plethoric IVC	Mitral inflow varies >25%

Pulsus by cuff: inflate above SBP, deflate ≤2 mm Hg per beat; subtract the pressure where every beat is heard from where sounds first appear (expiration only). Arterial line: SBP falls with each spontaneous inspiration.

5 Tamponade: what to do

1. Echo and drainage team now; large-bore IV, arterial line, defibrillator pads.
2. Bridge: a 500 mL bolus raised output in 47%, mainly if SBP <100 (Sagristà-Sauleda 2008); pressors only to buy time.
3. Keep the patient breathing spontaneously; avoid sedation and intubation until drained.
4. Echo-guided pericardiocentesis, drain left in: 97% success, 1.2% major complications (Tsang 2002).
5. Surgery for hemopericardium (trauma, rupture, dissection), pus, clot or loculated fluid; window for recurrent malignant effusion.
6. Arrest: compressions cannot fill a tamponaded heart; drain or reopen now.

Needle risks: RV or coronary laceration, arrhythmia, pneumothorax, vagal reaction. A drain that stops while BP falls means clot or reaccumulation.

SAFETY Diuretics, vasodilators, sedatives, β-blockers and positive-pressure ventilation can precipitate arrest. JVD here is compensation, not overload.

6 After surgery or MI, and constriction

Postop tamponade is often a posterior clot without Beck's triad. Arrest by day 10: resternotomy within 5 min (STS 2017).

Syndrome	Timing	Clues and care
Early postop tamponade	First 48 h: blood, clot	Tubes stop, CVP and PAD rise, CI falls; TEE; re-explore
Late postop tamponade	After day 5 (mean day 10)	Anticoagulants, valve surgery, wire removal; vague fatigue
Postpericardiotomy syndrome	Days to weeks, mostly month 1	Fever, pleuritic pain, effusions; aspirin plus colchicine
Early post-MI pericarditis	First days, transmural MI	Aspirin; no other NSAIDs or steroids (scar healing)
Dressler syndrome	Weeks to months; now <1%	Immune; aspirin plus colchicine
Constrictive pericarditis	Months to years	Edema, ascites, Kussmaul sign, knock; pericardiectomy

MORE Physiology: the pericardium and tamponade

The pericardium is a fibrous parietal sac lined by a serous layer that continues as the epicardium; it normally holds 10–50 mL of plasma ultrafiltrate (ESC 2015). Its pressure–volume curve rises slowly at first and then almost vertically, so a small bleed arriving in minutes after surgery or a perforation can tamponade the heart, while a slow malignant or uremic effusion stretches the sac over weeks to hold far more before pressure climbs.

For education and exam preparation only. Not medical advice; follow current guidelines and your institution's protocols. ER Basics is an independent study aid not affiliated with any certifying body.