ER BASICS · ONE-PAGER

Endocarditis and Valve Emergencies

Duke-ISCVID and ESC 2023 diagnosis, antibiotics, surgery and complications; bedside goals for acute valve lesions

24 sources + more detail
erbasics.com/sheets/endocarditis-valves.html
checked Oct 2026

ANATOMY Vegetations and abscess

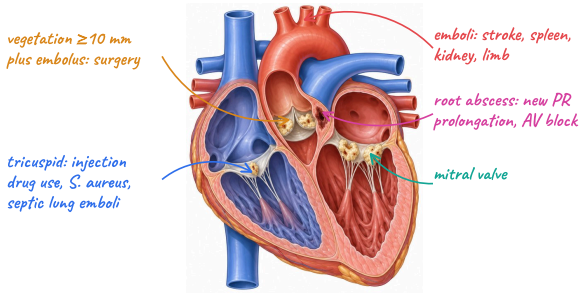

1 Endocarditis: suspect it

- Fever with a risk: prosthetic valve, prior IE, injecting drugs, CIED, lines, dialysis; any S. aureus bacteremia
- Signs: new murmur, emboli, Janeway lesions (painless), Osler nodes (painful), Roth spots, splinter hemorrhages

ORGANISM	TYPICAL SETTING
S. aureus (most common)	Drug use, lines; acute, destructive
Viridans streptococci	Dental source; subacute
Enterococci	Older adults; GU or GI source
S. gallolyticus (bovis)	Colon cancer: colonoscopy
Coagulase-negative staph	Prosthetic valve, first year

2 Diagnosis

1. Three culture sets from separate sticks before antibiotics (ESC 2023: 30 min apart); in sepsis, antibiotics right after
2. TTE first, then TEE in nearly all: prosthetic valve, device, negative TTE, abscess search
3. Repeat echo in 5–7 days if suspicion persists; cardiac CT for abscess, PET/CT for prosthetic valves

Definite IE (Duke-ISCVID, ESC 2023): 2 major, 1 major + 3 minor, or 5 minor. Major: typical organism in 2 culture sets; vegetation, abscess or fistula on echo, CT or PET. Minor: risk factor, fever >38 °C, emboli, immune signs.

3 Antibiotics

SITUATION	PLAN
Native or late prosthetic	Cover staph, strep, enterococci: e.g. vancomycin + ceftriaxone
Prosthetic <12 months, health care	ESC 2023: vancomycin + gentamicin + rifampin (IIb)
Organism known	Narrow it; native 2–6 weeks (often 4), prosthetic ≥6
Staph, prosthetic valve	Add rifampin; gentamicin: ESC yes, 2026 AHA no

- Count days from the first negative culture; vancomycin AUC 400–600
- Stable after ≥10 days IV, clean TEE: oral step-down (POET; ESC 2023 IIa)

4 Surgery: ESC 2023 indications

Emergency <24 h; urgent 3–5 days. ACC/AHA 2020 (Class 1) adds left-sided S. aureus or fungal IE and fever or bacteremia >5 days.

INDICATION	WHEN (CLASS)
Shock or refractory edema from the valve	Emergency (I)
Severe regurgitation with HF signs	Urgent (I)
Abscess, fistula, new AV block	Urgent (I)
Fungi or resistant organism	Urgent or same stay (I)
Bacteremia >1 week despite therapy	Urgent (IIa)
Vegetation ≥10 mm + embolus or other reason	Urgent (I)

5 Complications and antithrombotics

COMPLICATION	CLUES, THEN ACTION
Stroke or TIA	Neuro checks; CT or MRI; no lytics; thrombectomy possible
Root abscess	New PR prolongation or AV block: serial ECGs, TEE, surgery
Mycotic aneurysm	Headache, bleed: CTA or MRA; coil or clip if large, growing, ruptured
Spleen, kidney, limb emboli	LUQ or flank pain, hematuria, cold limb
AKI (about 18%)	Vancomycin, aminoglycoside, contrast, glomerulonephritis

- IE alone: no aspirin or anticoagulant (more bleeding, no fewer emboli)
- Major bleed or ICH: stop; mechanical valve: restart UFH early after team review
- Surgery likely (e.g. S. aureus), no stroke: warfarin or DOAC to UFH (ESC IIa)
- Surgery indicated after TIA or ischemic stroke without coma: no delay; after ICH, about 4 weeks if stable

EXAM TIP Injection drug use: tricuspid S. aureus IE with septic lung emboli; about 90% heal without surgery; treat the addiction too (ESC 2023 Class I).

6 Valve emergencies

Valve thrombosis: ACC/AHA 2020 Class 1 for lysis (alteplase 25 mg over 6 or 25 h) or surgery.

PROBLEM	CLUES	BRIDGE, THEN FIX
Papillary muscle rupture	Inferior MI, day 3–5; edema; v waves	Nitroprusside, IABP or Impella; surgery
Acute AR	IE or dissection; short diastolic murmur	Nitroprusside, inotrope, HR up; surgery
Critical AS	Syncope, HF; AF or low preload crashes it	Phenylephrine; cardiovert AF; TAVR or BAV
Mitral stenosis	AF, fever, pregnancy: pulmonary edema	β-blocker; warfarin if AF; valvotomy
Mechanical valve clot	Low INR; muffled clicks; HF, emboli	Heparin; slow low-dose alteplase or surgery
LVOT obstruction	SAM; worse on dobutamine; systolic murmur	Stop inotropes; fluid, esmolol, phenylephrine

SAFETY IABP helps acute MR but worsens acute AR and SAM. No nitrates in hypotensive AS; no dobutamine in SAM.

7 Bedside hemodynamic goals

Typical teaching (Miller, JACC Adv 2024; Sherrid, JAHA 2021).

LESION	PRELOAD	HEART RATE	SVR	CONTRACTILITY	AVOID
Aortic stenosis	Keep full	Slow-normal, sinus	Keep up	Maintain	Vasodilators, tachycardia, AF
Mitral stenosis	Adequate, not overloaded	Slow	Keep up	Maintain	Tachycardia, hypoxia, hypercarbia
Acute aortic regurgitation	Keep up	Faster	Lower	Support	Bradycardia, β-blockers, IABP
Acute mitral regurgitation	Lower if congested	Normal to fast	Lower	Support	Rising SVR, bradycardia
LVOT obstruction (SAM)	Keep full	Slow	Keep up	Lower (β-blocker)	Inotropes, nitrates, diuretics, IABP

MORE How endocarditis forms, who gets it and how it presents

Turbulent jets, catheters, device leads and injected particles injure valve endothelium, and platelets and fibrin settle there as a sterile thrombus. Bacteremia from teeth, skin, gut or a line seeds it, and good adherers, above all S. aureus, which can also invade intact endothelium, build a vegetation of fibrin, platelets and bacteria in a biofilm. There, dense, slow-growing bacteria are shielded from neutrophils and tolerate antibiotics, so cure takes weeks of bactericidal therapy or surgery (ESC 2023).

For education and exam preparation only. Not medical advice; follow current guidelines and your institution's protocols. ER Basics is an independent study aid not affiliated with any certifying body.