ER BASICS · ONE-PAGER

Meningitis and Encephalitis

First-hour care, empiric antibiotics, dexamethasone, CT before LP, CSF patterns, HSV and autoimmune encephalitis, isolation and ICU complications

24 sources + more detail
erbasics.com/sheets/cns-infections.html
checked Oct 2026

ANATOMY Meninges, temporal lobe, EVD

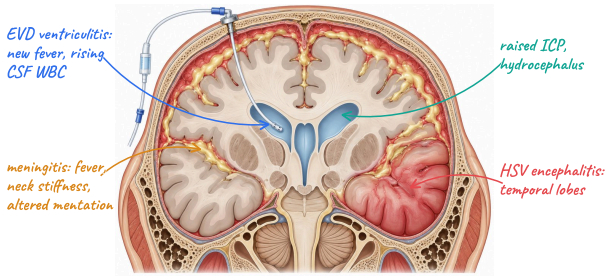

1 Recognize and treat within the hour

- Fever, neck stiffness and altered mentation coexist in 44%; adding headache, 95% have two or more (van de Beek 2004)
- Kernig and Brudzinski signs: 5% sensitive (Thomas 2002); absence rules nothing out
- Petechiae or purpura: treat as meningococcus
- Behavior change, aphasia, focal seizures or hallucinations suggest encephalitis: add acyclovir

1. Blood cultures, plus LP if no CT criteria and no delay; then dexamethasone and antibiotics within 1 h of arrival (ESCMID 2016, UK 2016, WHO 2025)
2. CT only if criteria below; LP as soon as safe, ideally within 4 h of starting antibiotics (UK 2016)

⚠ SAFETY Never hold antibiotics for CT or LP: LP after CT carried higher mortality (10% vs 4%, Glimåker 2018).

2 Empiric antibiotics and dexamethasone

IDSA 2004, 2017. Listeria age cut-off: 50 (IDSA, ESCMID 2016) or 60 (UK 2016, WHO 2025). UK, WHO: vancomycin only for resistance risk. Vancomycin: load 20–35 mg/kg, then AUC 400–600 per pharmacy (2020 consensus).

PATIENT	TYPICAL ADULT REGIMEN
Community, age 18–50	Ceftriaxone 2 g IV q12h + vancomycin 15–20 mg/kg q8–12h
Over 50, pregnant or immunocompromised	Add ampicillin 2 g IV q4h (Listeria)
Neurosurgery, EVD, shunt, penetrating trauma	Vancomycin + cefepime, ceftazidime or meropenem 2 g q8h
Encephalitis features	Add acyclovir 10 mg/kg IV q8h

- Dexamethasone 10 mg IV q6h for 4 days (IDSA: 0.15 mg/kg), first dose 10–20 min before or with antibiotics
- Antibiotics already started: IDSA skips it; ESCMID allows up to 4 h, UK 2016 up to 12 h
- Continue for pneumococcus; stop for other causes
- Deaths 7% vs 15% (de Gans 2002); less hearing loss (Cochrane 2015)

3 CT before LP

IDSA 2004 scans first for immunocompromise, known CNS lesion, seizure within 1 week, papilledema, abnormal consciousness or focal deficit. ESCMID 2016 is narrower: GCS below 10, focal signs, new seizures, severe immunosuppression; WHO 2025 adds papilledema.

Also defer LP for unstable airway or circulation, spreading rash, coagulopathy (platelets under 40, UK 2016) or site infection.

4 CSF patterns

WBC per µL; neutrophils can lead early in viral and TB meningitis. Antibiotics lower Gram stain and culture yield.

CSF	WBC	GLUCOSE	PROTEIN, CLUE
Normal	0–5, lymphocytes	About 60% of serum	15–45 mg/dL; pressure 10–25 cm H_2O
Bacterial	1,000–5,000, neutrophils	Under 40 mg/dL; ratio ≤0.4	High; pressure 20–50; Gram stain
Viral	Under 1,000, lymphocytes	Normal	Normal or mildly high
HSV	Mild, lymphocytes; RBCs	Normal	Mildly high; HSV PCR
Cryptococcal	Often few, lymphocytes	Low	High; pressure often ≥25; antigen
Tuberculous	10–500, lymphocytes	Low; ratio under 0.5	Over 100 mg/dL; basal enhancement

5 HSV and autoimmune encephalitis

- HSV-1: fever, confusion, behavior change, aphasia, temporal lobe seizures; MRI temporal signal
- Acyclovir 10 mg/kg IV q8h (ideal weight if obese), ideally within 6 h of arrival (EAN/ESCMID 2026); 14–21 days if proven
- An LP within 72 h of onset can give a false-negative PCR: keep acyclovir, repeat in 2–3 days if still suspected
- Kidneys: infuse over 1 h at ≤7 mg/mL and hydrate (label); creatinine daily, renal dosing; tremor or confusion can be toxicity
- Steroids did not help HSV encephalitis (DexEnceph 2026)
- Autoimmune (anti-NMDAR) encephalitis: psychiatric onset, dyskinesias, autonomic swings, hypoventilation; 27% after HSV (Armangue 2018); steroids, IVIG or plasma exchange; teratoma search

6 Isolation, contacts and EVD infection

- Droplet precautions for suspected meningococcus or Hib until 24 h of effective therapy; standard otherwise (CDC)
- Prophylaxis, ideally within 24 h: household, kissing, staff with unmasked intubation or suctioning; not routine care
- Adults: ciprofloxacin 500 mg PO once, ceftriaxone 250 mg IM once, or rifampin 600 mg q12h for 2 days (CDC)
- EVD ventriculitis: new fever, worse mental status, rising CSF WBC; send culture; vancomycin + cefepime or meropenem; remove or replace the drain (IDSA 2017)

7 ICU complications and neuro checks

Rates: Dutch adult cohorts (Zoons 2008, Brouwer 2007, Schut 2012).

PROBLEM	CLUE	ACTION
Raised ICP, hydrocephalus	Falling GCS, pupil change	HOB 30°, osmotherapy, CT, EVD
Seizures (17%)	Twitching, fluctuating GCS	Benzodiazepine; EEG
Hyponatremia (30%)	Falling sodium	No routine fluid restriction
Infarction (25%)	New focal deficit	Urgent imaging
Shock, DIC, purpura	Cold limbs, spreading rash	Sepsis bundle
Hearing loss	Ask and test	Audiology before discharge

Check GCS, pupils, cranial nerves and limbs at least hourly while unstable. ICU for GCS ≤12, a fall of more than 2, uncontrolled seizures or fast-spreading rash (UK 2016).

For education and exam preparation only. Not medical advice; follow current guidelines and your institution's protocols. ER Basics is an independent study aid not affiliated with any certifying body.