ER BASICS · ONE-PAGER

CEN Adult Medical Pearls: Neuro, GI and Respiratory Look-alikes

Drug-induced delirium, valproate hyperammonemia, myasthenia at the bedside, lumbar puncture care, antiplatelet head bleeds, open depressed fractures, meningococcal contacts in pregnancy, food impaction, acalculous cholecystitis, Grey Turner sign, sump tubes and pneumonia that hides

23 sources + more detail
erbasics.com/sheets/cen-medical-look-alikes.html
checked Oct 2026

DEVICE Salem sump: keep the vent open

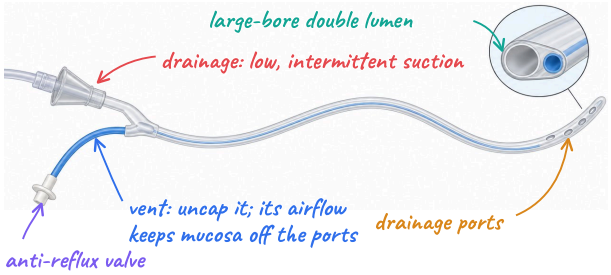

1 Confusion that a drug explains

PICTURE	TRAP	POINT
Older adult confused after a nighttime sleep aid	Swap it for hydroxyzine or another antihistamine	First-generation antihistamines (diphenhydramine, doxylamine, hydroxyzine, meclizine, promethazine) are all Beers drugs: highly anticholinergic, cleared slowly with age
On valproate, lethargy and vomiting, normal liver tests	Normal LFTs rule out ammonia	Valproate raises ammonia despite normal LFTs; measure it. Topiramate added to valproate is a labeled cause

Beers 2023, delirium: avoid anticholinergics, antipsychotics, benzodiazepines, corticosteroids, H2 blockers, Z-drugs and opioids in patients with or at high risk of delirium. Valproate label: if ammonia is high, valproate is stopped; unexplained hyperammonemic encephalopathy prompts a urea cycle disorder workup.

2 Myasthenia and the lumbar puncture

QUESTION	ANSWER
Ptosis and diplopia worse by evening	Ice pack over the closed eye 2 min: ptosis improves (about 80% sensitive)
Pupil in myasthenia	Normal; a dilated pupil points elsewhere (third nerve palsy)
Sustained upgaze	Ptosis worsens (fatigue), it does not improve
Edrophonium test	No longer available in the US; antibodies or EMG confirm
LP with opening pressure	Lateral decubitus, knees up; manometry cannot be done sitting. Normal 7 to 18 cm CSF
After the LP	No bed rest needed; it does not prevent headache (about 10%). Report persistent or worsening back pain

3 Head injury: two traps

- Aspirin or clopidogrel with a normal platelet count: the count is normal, the platelets are not. Clopidogrel blocks P2Y12 irreversibly for the platelet lifespan (7 to 10 days) though its active metabolite lasts about 30 min.
- Platelet transfusion is not the reflex: PATCH found it worse than standard care in spontaneous ICH; NCS/SCCM 2026 advises against it in nonsurgical spontaneous ICH and makes no call for traumatic ICH.
- Open depressed skull fracture deeper than the skull is thick: antibiotics and early surgery (elevation and debridement), not a pressure dressing and observation. Sterile dressing; avoid pressure over the fragment (classic teaching).
- Tetanus: dirty or major wound and last dose 5 or more years ago means a booster (CDC).

4 Meningococcal contact who is pregnant

CDC REGIMEN (ADULT)	PREGNANCY
Ceftriaxone 250 mg IM once (15 years and older)	No restriction listed; use when clearly needed (label)
Rifampin 600 mg every 12 h for 2 days	Not recommended
Ciprofloxacin 500 mg orally once	Not recommended

Close contacts get prophylaxis as soon as possible, regardless of vaccination status; after 14 days it is of little or no benefit. Full table on Meningitis and Encephalitis.

5 GI look-alikes

PICTURE	TRAP	POINT
Young atopic man, third food impaction	Barium swallow, or glucagon and home	Eosinophilic esophagitis: biopsies at the same endoscopy (15 or more eosinophils per field); scope can look normal
Critically ill, fever, RUQ tenderness, no stones	No stones, not the gallbladder	Acalculous cholecystitis: cultures, antibiotics and source control (cholecystectomy, or percutaneous cholecystostomy if surgical risk is very high)
Pancreatitis, new flank bruising, falling hematocrit	Enoxaparin bruises	Grey Turner sign: hemorrhagic exudate, under 3% of cases, poor prognosis. Report now, watch for shock
Sump tube on suction, vent capped, output falls	Air bolus check or more suction	Uncap the vent: its airflow keeps mucosa off the drainage ports

6 Pneumonia that hides or mimics

PICTURE	TRAP	POINT
After influenza, shock, cavitary multilobar infiltrates	Ceftriaxone and azithromycin are enough	Think S. aureus including MRSA: add vancomycin or linezolid
Older adult, fall, new confusion, no fever or cough, crackles	Urine culture, or haloperidol	Pneumonia often presents this way: chest imaging
Weeks of cough, foul sputum, cavity with air-fluid level in a dependent segment	Standard CAP regimen, or TB drugs	Anaerobic lung abscess: ampicillin-sulbactam, usually 3 to 6 weeks

EXAM TIP ATS/IDSA 2019: no routine anaerobic coverage for aspiration pneumonia unless lung abscess or empyema is suspected.

7 Exam pearls

- Stopping the culprit drug is half the job; do not replace it with one from the same class.
- A normal count or a normal liver panel can hide the problem: think function and ammonia.
- Cold helps myasthenic ptosis; upgaze makes it worse.
- Bed rest after an LP is not a headache prevention.
- Recurrent food impaction in a young adult is a biopsy, not a barium study.
- A sump without an open vent is a single-lumen tube that clogs and injures mucosa.
- A cavity after influenza is MRSA until proven otherwise; a foul one in a drinker is an abscess.

For education and exam preparation only. Not medical advice; follow current guidelines and your institution's protocols. ER Basics is an independent study aid not affiliated with any certifying body.