ER BASICS · ONE-PAGER

CEN: Uterine Bleeding, Kidney Stones and Deep Neck Infections

Acute heavy uterine bleeding, adolescents and von Willebrand disease, postmenopausal bleeding, the normal urinalysis and uric acid stones, Lemierre syndrome, descending mediastinitis, the pulsatile neck "abscess", drug-induced angle closure and the locked jaw

16 sources + more detail
erbasics.com/sheets/cen-gyn-gu-neck-infections.html
checked Oct 2026

ANATOMY When a neck infection spreads

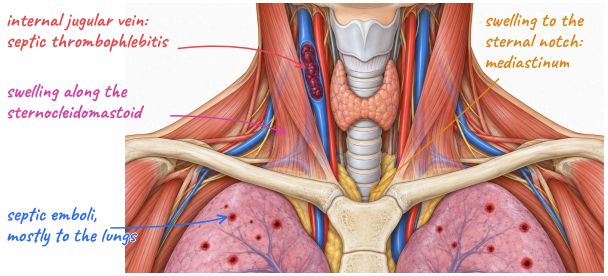

1 Who goes first

PICTURE	THINK	FIRST MOVE
Soaking pads, tachycardia, low BP, faint on standing	Hemorrhage from acute AUB	Access, blood, IV estrogen or tranexamic acid, gynecology now
Sore throat days ago, now rigors, lateral neck pain, lung nodules	Lemierre syndrome	Blood cultures, anaerobic cover, contrast CT neck
Days after a neck or dental abscess: chest pain, crepitus, sepsis	Descending necrotizing mediastinitis	Airway watch, contrast CT neck and chest, surgery
Warm neck swelling that pulsates, in a person who injects into the neck	Infected pseudoaneurysm until imaged	Hold the incision; CT angiography or Doppler first
Both eyes painful and blurred days after starting topiramate	Drug-induced angle closure (effusion)	Stop the drug; question pilocarpine and iridotomy

⚠ SAFETY Any reproductive-age bleeding: pregnancy test first (see CEN: Genitourinary, Gynecologic and Early-Pregnancy Emergencies).

2 Acute heavy uterine bleeding

- Unstable: IV crystalloid and blood as needed (Merck), CBC, coagulation tests; large-bore access and crossmatch are usual practice.
- Conjugated estrogens 25 mg IV every 4 to 6 h, 4 doses; or tranexamic acid 10 mg/kg IV (max 600 mg) or 1.3 g orally, three times daily for 5 days.
- Still bleeding: intrauterine balloon (catheter with 30 to 60 mL), D&C, uterine artery embolization; hysterectomy if unstable and uncontrolled.
- High-dose estrogen, progestin and tranexamic acid raise clot risk: ask about prior DVT and cardiovascular risk.
- Stable: COC (35 mcg) three times daily or medroxyprogesterone 20 mg three times daily, each for 7 days; iron; NSAID cuts loss about 25 to 35%.

3 Adolescents and von Willebrand disease

CLUE	MEANING
Pad or tampon every 1 to 2 h, over 7 days, grape-size clots, anemia	Heavy menstrual bleeding (CDC)
Nosebleeds over 10 min, 5 or more a year	Think bleeding disorder
Anemia or admission for bleeding	Test: platelets, PT, PTT, then VWD panel
Stress, acute bleeding, estrogen drugs	Raise VWF and can hide VWD: draw early

VWD is the commonest bleeding disorder (up to 1% in the US), and heavy menses can be its first sign. Stable, normal tests, mild anemia: hormonal therapy, iron, close follow-up.

4 Bleeding after menopause

- Never "wait for the checkup": 6 to 19% have endometrial cancer, and over 90% of these cancers present with bleeding.
- Risk: obesity, unopposed estrogen, tamoxifen over 2 years, Lynch syndrome, pelvic radiation, age over 45.
- Workup: endometrial biopsy, or transvaginal ultrasound if average risk; sample if the lining is over 4 to 5 mm (Merck pages give 4 mm and 4 to 5 mm) or bleeding persists.
- Normal vital signs only show she is not hemorrhaging; the ED job is a prompt gynecology referral.

5 Stones: two points to add

- A urinalysis without blood does not exclude a stone: urine can be normal despite several calculi. Keep the workup going.
- Uric acid stones (5 to 10%) form in acid urine, pH below 5.5. Prevention: urine at least 2.5 L a day and potassium citrate to pH 6 to 6.5; alkalinizing can occasionally dissolve them.
- Do not acidify the urine or cut calcium: stone formers keep normal calcium (about 1,000 mg a day).

6 When a neck infection spreads

COMPLICATION	CLUES	PLAN
Lemierre syndrome	Healthy young adult, pharyngitis several days before, swelling along the sternocleidomastoid, septic lung emboli	Contrast CT, blood cultures, beta-lactam or carbapenem with metronidazole for 3 to 5 weeks
Descending mediastinitis	Retrosternal pain, dyspnea, crepitus at the neck base, septic shock	Contrast CT neck and chest, cervical and mediastinal drainage
Carotid erosion or mycotic aneurysm	Expanding pulsatile mass, fever, bleeding; neck injection	Imaging before any needle or knife; vascular surgery

7 Two HEENT traps

Topiramate angle closure: both eyes, myopic shift, shallow chambers, high pressure, usually within a month of starting (often the first 2 weeks). Ciliochoroidal effusion pushes lens and iris forward, so stopping the drug is the main treatment; cycloplegia and topical steroids help; pilocarpine and iridotomy do not help and may harm.

Locked jaw while waiting for reduction: drooling and poor swallowing mean aspiration risk. Keep the airway clear: upright, suction within reach, and ask the reducing clinician about nothing by mouth (sedation may be needed). These steps are nursing practice, not stated in the sources.

8 Exam pearls

- Shock from uterine bleeding is treated before the ultrasound.
- Lifelong nosebleeds plus heavy first periods: coagulation and VWD tests before hormones.
- Postmenopausal spotting always gets endometrial evaluation.
- Uric acid stones: make the urine less acidic, not more.
- Chest pain after a neck abscess is mediastinitis until CT says otherwise.
- A pulsatile "abscess" is not incised.

For education and exam preparation only. Not medical advice; follow current guidelines and your institution's protocols. ER Basics is an independent study aid not affiliated with any certifying body.