ER BASICS · ONE-PAGER

Capnography

Normal values, waveform patterns, CPR and ROSC, tube checks and sedation monitoring

18 sources + more detail
erbasics.com/sheets/capnography.html
checked Oct 2026

SET-UP Where the CO_2 is read

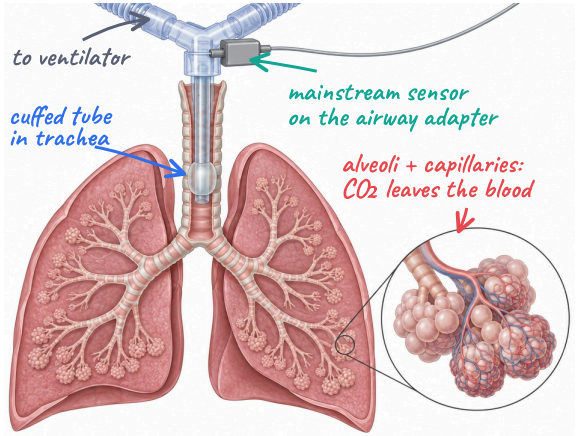

1 Normal values and phases

$EtCO_2$: the CO_2 at the end of each exhaled breath. Typical adult values for exam study.

ITEM	NORMAL
$EtCO_2$	35–45 mm Hg
$PaCO_2$ minus $EtCO_2$	About 2–5 mm Hg
Baseline	Returns to zero
Shape	Rectangular: steep rise, plateau flat or gently rising

PHASE	WHAT IT SHOWS
I	Flat baseline: dead-space gas, no CO_2
II	Steep upstroke as alveolar gas arrives
III	Alveolar plateau; $EtCO_2$ read at its end
Downstroke	Inspiration: falls to zero (phase 0; some texts say IV)

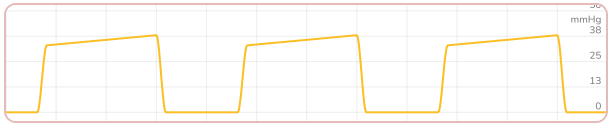

Normal: zero baseline, steep upstroke, gently rising plateau peaking near 38 mm Hg, sharp drop on inspiration.

A wider $PaCO_2$–$EtCO_2$ gap means more dead space: low cardiac output, hypovolemia, PE, emphysema. The gap varies in sick lungs, so match $EtCO_2$ to an ABG before trending it.

2 Patterns and causes



Shark fin: sloping upstroke, no plateau. Bronchospasm or a kinked or plugged tube.

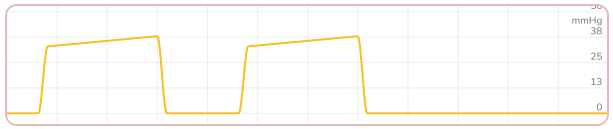

Sudden loss: normal breaths, then flat at zero. Disconnection, dislodged tube, complete obstruction or apnea until proven otherwise.

PATTERN	THINK
Sudden drop to zero	Disconnection, extubation or dislodged tube, complete obstruction, apnea
Sudden drop, not to zero	Leak, partial obstruction, abrupt fall in cardiac output (PE, arrest)
Sudden rise	ROSC, IV sodium bicarbonate, tourniquet release
Gradual rise	Hypoventilation, fever; malignant hyperthermia if it climbs despite more ventilation
Gradual fall	Hyperventilation, hypothermia, falling cardiac output
Shark fin	Bronchospasm (asthma, COPD), kinked or plugged tube
Baseline above zero	Rebreathing, exhausted CO_2 absorber, contaminated sensor
Notch in plateau	Curare cleft: breathing effort as paralysis wears off

⚠ SAFETY When the trace suddenly flattens, assess the patient before the monitor: tube, circuit, breathing, pulse.

💡 EXAM TIP Exams pair shark fin with bronchospasm, sudden zero with a disconnected or dislodged tube, and gradual rise with hypoventilation.

3 CPR quality and ROSC (AHA 2025)

During CPR, $EtCO_2$ mainly reflects the blood flow compressions generate. The 2025 algorithm: if $EtCO_2$ is low or falling, reassess CPR quality.

$ETCO_2$ DURING CPR	SUGGESTS
Under 10 mm Hg	Little flow: check depth, rate, recoil, pauses; swap compressors
10 or more, ideally 20 or more	Linked to adequate compressions and more ROSC
Abrupt, sustained rise	Possible ROSC (a jump over 10 mm Hg is suggestive; smaller rises occur); confirm with pulse or arterial line
10 or less after 20 min of ALS, intubated	One factor in deciding to stop, never the only one

Ventilation rate, epinephrine and sodium bicarbonate also shift $EtCO_2$. With an advanced airway, give 1 breath every 6 seconds.

💡 EXAM TIP Low or falling $EtCO_2$: fix compressions, check the ventilation rate, confirm the tube. Abrupt sustained rise: check for ROSC. Older materials quote about 40 mm Hg; the 2025 guideline names no cutoff.

⚠ SAFETY In patients who are not intubated, no $EtCO_2$ cutoff should be used to stop resuscitation (AHA 2025, Class 3: Harm).

4 Confirming tube placement

- In cardiac arrest, waveform capnography plus clinical assessment is the most reliable way to confirm and monitor the tube (AHA 2025, Class 1). ASA standards: verify every tracheal tube or supraglottic airway with exhaled CO_2.
- Look for sustained CO_2: peaks that rise and fall with each breath and hold or grow over at least 7 breaths. CO_2 that fades suggests the esophagus.
- In arrest, CO_2 can be low, but good compressions should not leave a completely flat trace.
- Colorimetric detector: purple = no CO_2, yellow = CO_2; check the device's key. Arrest can give a false negative; gastric acid or drugs, a false positive that does not change breath to breath.
- Keep monitoring; sudden loss may be the first sign of dislodgement.

⚠ SAFETY No trace = wrong place, even in arrest. Consensus guidance makes removing the tube the default; if it stays, recheck with video laryngoscopy, bronchoscopy or ultrasound. Breath sounds cannot rule out the esophagus.

5 Sedation and opioids

ASA standards (amended 2025): during moderate or deep sedation, observe ventilation continually and make every effort to monitor exhaled CO_2.

- Capnography shows hypoventilation and apnea before SpO_2 falls, especially when oxygen keeps saturation up (procedural sedation, opioid PCA). It is linked to fewer desaturations.
- Slow breathing (typical of opioids): high $EtCO_2$, tall, wide waveform.
- Shallow breathing (typical of sedative-hypnotics): small waveform, normal or low number, while $PaCO_2$ rises. A low reading is not reassuring.
- Shrinking or absent waveform while the chest moves: obstruction; open the airway.
- Flat line, no effort: apnea; stimulate and ventilate.
- Oxygen dilutes nasal cannula samples, so readings run low; compare trend and shape with baseline.

For education and exam preparation only. Not medical advice; follow current guidelines and your institution's protocols. ER Basics is an independent study aid not affiliated with any certifying body.