ER BASICS · ONE-PAGER

Acute Abdomen and GI Surgical Emergencies

Obstruction and NG decompression, ileus and Ogilvie, mesenteric ischemia, perforation, Whipple and bariatric leaks, dumping and Fournier gangrene

28 sources + more detail
erbasics.com/sheets/acute-abdomen.html
checked Oct 2026

ANATOMY Reading the acute abdomen

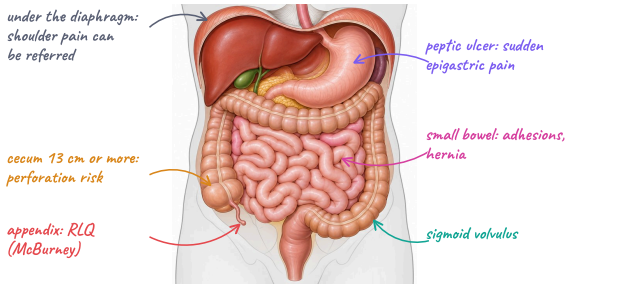

1 Red flags and first actions

FINDING	THINK	DO NOW
Severe pain, soft abdomen (pain out of proportion)	Mesenteric ischemia	CT angiography now; a normal lactate does not reassure
Colicky pain turns constant, fever, HR up	Strangulated bowel	Surgeon now
Sudden severe pain, rigid board-like abdomen, quiet bowel sounds	Perforation, peritonitis	NPO, notify at once, IV access, fluids and antibiotics as ordered
Appendicitis pain suddenly eases, then the abdomen hardens	Ruptured appendix	Notify at once; prepare for surgery
HR above 120 and fever after a sleeve or bypass	Staple-line or anastomotic leak	NPO, notify, expect CT or OR

- Steroids and immunosuppressants blunt pain, tenderness and WBC: image early.
- Moderate IV opioid doses do not mask peritoneal signs and do not increase diagnostic error (Cochrane; 12 trials pooled in 2019): do not withhold analgesia. The hydromorphone label lists known or suspected bowel obstruction, including ileus, as a contraindication because opioids slow the gut; in practice opioids are still commonly used for pain in obstruction, so clarify the order and dose, give it as clarified, and watch distension and bowel sounds rather than leave pain untreated.
- Shoulder pain can be referred from blood or infection under the diaphragm.
- Abdominal compartment syndrome: bladder pressure above 20 mm Hg with new organ dysfunction (ICU Basics: Trauma: Primary and Secondary Survey).

2 Bowel obstruction

FEATURE	SMALL BOWEL	LARGE BOWEL
Common causes	Adhesions, hernia; tumor if no prior surgery or hernia	Tumor, diverticulitis, volvulus
Picture	Early vomiting, colicky pain, high-pitched sounds	Gradual distension, vomiting late
Danger	Strangulation in nearly 25%; infarction in as little as 6 h	Cecum 13 cm or more: perforation risk

- Care: NPO, NG suction, IV 0.9% saline or LR, replace K and Na, urinary catheter for output.
- Partial adhesive SBO with a soft abdomen: about 85% settle with decompression (trial up to 72 h).
- Operate for peritonitis, constant pain, fever, rising lactate, a closed loop, gas in the bowel wall, or failure to improve.
- Sigmoid volvulus: scope decompression, then planned resection (it recurs without it).

3 NG decompression: nursing

- Low intermittent suction, usually 40-60 mm Hg, not above 80.
- Nausea or distension with little drainage: check kinks, the tube mark at the nares and the suction first; irrigate as ordered (often 30 mL).
- Never turn the suction to continuous high to clear it.
- Record output color and volume; high output means fluid and potassium loss to replace.
- Bright red drainage after gastric surgery: vital signs, notify; do not reposition the tube.

4 Ileus and Ogilvie syndrome

FEATURE	POSTOPERATIVE ILEUS	OGILVIE (COLONIC PSEUDO-OBSTRUCTION)
Picture	Distension, no flatus, quiet abdomen; colon slowest (48-72 h)	Huge colon (cecum to splenic flexure), no blockage; older, after surgery or illness
Care	Walk early, limit opioids, NG if vomiting, K above 4 mEq/L	NPO, NG and rectal tube, fix electrolytes, stop opioids and anticholinergics
Escalate	Beyond 1 week: look for a mechanical cause	Cecum above 12 cm or no response: neostigmine or colonoscopic decompression

⚠ SAFETY Neostigmine causes bradycardia: continuous cardiac monitoring with atropine at the bedside. Mechanical obstruction must be excluded first.

5 Acute mesenteric ischemia

TYPE (MERCK SHARE)	CLUE	TREATMENT
Arterial embolus (over 40%)	Sudden pain; AF, heart disease	Heparin, embolectomy or endovascular
Arterial thrombosis (30%)	Atherosclerosis; pain after meals beforehand	Heparin, revascularization
Venous thrombosis (15%)	Gradual; clotting disorder, pancreatitis	Heparin infusion; surgery only for peritonitis
Nonocclusive (15%)	Shock, vasopressors, after bypass	Restore flow, cut vasoconstrictors

- Lactate rises only once bowel dies. CT angiography without delay, even with AKI.
- Fluids, NG tube, broad-spectrum antibiotics, heparin; planned second look 24-48 h after resection.
- Ischemic colitis is milder: left lower quadrant pain, then bloody stool (after aortic surgery, low flow).

6 Perforation

SITE	CLUE	KEY POINT
Peptic ulcer	Sudden epigastric pain, then rigid abdomen; NSAIDs	Free air often missing on films: CT; never barium; surgery as soon as possible
Appendix	Periumbilical pain moves to the RLQ (McBurney) in 12-24 h; pain suddenly eases, then spreads	A normal WBC does not exclude; CT in adults, ultrasound in children and pregnancy
Colon after colonoscopy	Pain, distension, fever, tachycardia, mostly within 48 h	CT; small tears found at once can be clipped
Esophagus (Boerhaave)	Forceful vomiting, chest pain, subcutaneous emphysema	CT with water-soluble contrast; NPO, antibiotics, surgery

7 After GI surgery

PROBLEM	CLUE	ACTION
Pancreatic fistula after Whipple	Drain amylase above 3 times the serum upper limit of normal, with fever or other consequence	Keep drain; notify; antibiotics, drainage
Bile leak	Green drain fluid, drain bilirubin above serum	Notify; drainage
Late bleeding after Whipple	Blood in the drain or NG after the first day (late bleed)	Call at once; angiography and embolization
Delayed gastric emptying	Vomiting, high NG output	NG decompression, nutrition support, prokinetics
Dumping after gastrectomy or bypass	Early (within 1 h): cramps, diarrhea, sweating, dizziness. Late (1-3 h): low glucose	Small high-protein meals, no simple sugars, no fluids for 30 min after meals

8 Fournier gangrene

- Necrotizing fasciitis of the perineum, scrotum or vulva; polymicrobial; diabetes is the classic risk.
- Pain out of proportion (less with neuropathy), swelling, dusky skin, crepitus, sepsis.
- Surgeon now for debridement, repeated until no dead tissue; broad IV antibiotics; scores and imaging must not delay surgery.
- Testes are usually spared: their blood supply comes from the aorta.
- Soft-tissue infection basics and antibiotics: ICU Basics page CEN: Musculoskeletal and Wound Emergencies.

For education and exam preparation only. Not medical advice; follow current guidelines and your institution's protocols. ER Basics is an independent study aid not affiliated with any certifying body.